

NIIOS Newsletter

Netherlands Institute for Innovative Ocular Surgery

Laan op Zuid 88
3071 AA Rotterdam - The Netherlands
Tel +31 10 297 4444 - Fax +31 10 297 4440
info@nios.com - www.nios.com



PAGE 2
**FROM DMEK TO DMET:
IS THE CONCEPT OF
'KERATOPLASTY' GOING
TO DISAPPEAR?**

PAGE 3
**2012 EEBA MEETING IN
ROTTERDAM**

PAGE 4
"BACK TO BUSINESS"

**MI-ESC MEETING /
NIIOS WETLAB COURSES**



REFERRALS TO MELLES CORNEA CLINIC ROTTERDAM

For referrals to Melles Cornea Clinic Rotterdam, please use the referral form enclosed, or download it from www.nios.com.

Please fax the referral form to +31 10 297 4440 and one of our international secretaries will make further arrangements.

To contact us by e-mail, please contact us at info@corneaclinic.nl.

≤20/60 visual acuity has been a criterion for penetrating keratoplasty, but new lamellar transplantation techniques may set different standards

DMEK corneal transplantation even though one can still see 20/20

In the past few years, several patients have undergone DMEK in the Cornea Clinic Rotterdam despite a visual acuity of 20/20. However, the preoperative visual acuity level may hold little information on the severity of Fuchs endothelial dystrophy. Even though patients may perform well in reading 'hard-contrast' letter charts, they may be severely handicapped under ambient light circumstances. Penetrating keratoplasty has often been postponed until the visual acuity dropped to 20/60 or worse, because the surgical outcome was often disappointing. As a result of this 'backwards rule', many Fuchs patients are still denied treatment for years. Today, DMEK may offer full visual rehabilitation, including normal contrast sensitivity and color perception, so that the '≤20/60 rule-of-thumb' may not be a proper guideline anymore.

Truck driver Mr. Spijkers was utterly frustrated upon his arrival at Melles Cornea Clinic
**"Nobody took me seriously:
I had 20/20 vision, so I shouldn't complain!"**

"I run my own transport company and drive my own truck throughout Europe. Driving at night became really nerve-wracking: disturbing halos appearing around each light source and oncoming traffic would completely blind me. Over a period of several years, I had slowly been losing my sight. I visited several opticians and ophthalmologists, but none of them acknowledged my problems. They diagnosed me with Fuchs endothelial dystrophy, but my visual acuity was 20/20, so what was the big deal? I would only be eligible for a corneal transplant, if my visual acuity dropped to 20/60.

My whole life was falling apart before my eyes. My company was going down the drain, my family suffered immensely, and I felt completely stuck because there was no hope for visual improvement and nobody could help me out. They implied it was all due to 'stress'. And I could not deny that I was under a lot of stress because of this situation. Thank God I have a fantastic wife, who searched the internet to learn more about Fuchs endothelial dystrophy.

One day she told me that she had found a clinic in Rotterdam. At first I was rather skeptical. If any treatment existed, they should have told me about it in one of the hospitals. But eventually she contacted the Melles Cornea Clinic by e-mail, and we made an appointment for a consultation. After that, things went very quickly. Everything was well explained, and I was scheduled for surgery.


Three days after surgery, my sight was already pretty good, with black being black and red being red again. During the recovery period my whole life revolved around driving back and forth to the clinic, taking my eye drops, and checking if the transplant was still working.

But I am really happy! We made a fresh start with the company and I can work again. My life completely changed for the better, and I can drive long distances like I used to. I am so thankful that I could have the surgery done and can't wait until my other eye is operated on also. Fantastic! I can't give Dr. Melles and his whole team enough gratitude for all they have done for me!"



Mr. Spijkers standing next to his truck. Despite a pre-operative visual acuity of 20/20, he was not able to drive safely due to Fuchs endothelial dystrophy.

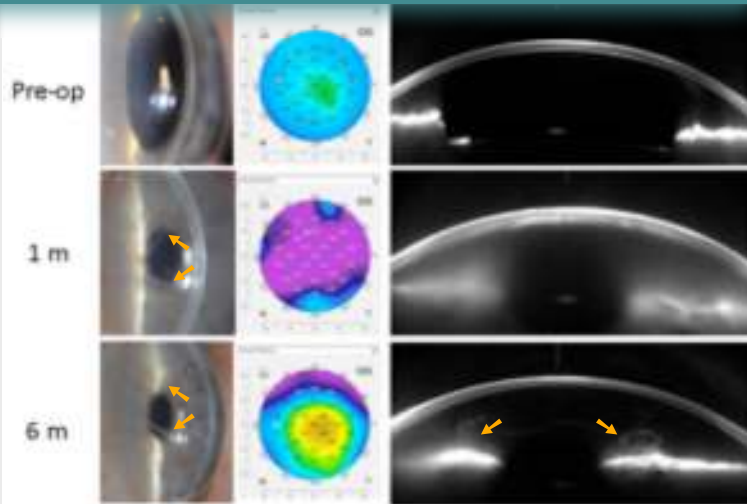
Cornea & Research fellows 2011/2012



Left-to-right: Ru-Yin Yeh, Belgium; Ruth Quilendrino, Phillipines; Fayyaz Musa, UK; Maya Tong, Canada; and Jack Parker, USA

NIIOS scientific articles 2011/2012

- ♦ Dieleman M, Wefers Bettink-Remeijer M, Jansen J, Hoppenreijts VPT, van der Pol R, Baarsma S, van Dijk K, de Waard- van der Spek FB, van Wijk RG, Zijlman BLM. High incidence of adverse reactions to locoregional anaesthesia containing hyaluronidase after uneventful ophthalmic surgery. Acta Ophthalmol. In press.
- ♦ Parker J, Dirisamer M, Naveiras M, Tse WHW, van Dijk K, Frank LE, Ham L, Melles GRJ. Outcome of Descemet membrane endothelial keratoplasty in phakic eyes. J Cataract Refract Surg. In press.
- ♦ Naveiras M, Dirisamer M, Parker J, Ham L, van Dijk K, Dapena I, Melles GRJ. Causes of glaucoma after Descemet membrane endothelial keratoplasty (DMEK). Am J Ophthalmol. In press.
- ♦ Dirisamer M, van Dijk K, Dapena I, Ham L, Oganesyan O, Frank LE, Melles GRJ. Prevention and management of graft detachment in Descemet membrane endothelial keratoplasty. Arch Ophthalmol. In press.
- ♦ van Luijk CM, Bruinsma M, van der Wees J, Lie JT, Ham L, Melles GRJ. Combined chlorhexidine and PVP-I decontamination of human donor eyes prior to corneal preservation. Cell and Tissue Banking. In press.
- ♦ Dirisamer M, Ham L, Dapena I, van Dijk K, Melles GRJ. Descemet membrane endothelial transfer (DMET): 'Free floating' donor Descemet implantation as a potential alternative to 'keratoplasty'. Cornea 2012;31:194-7.
- ♦ Dirisamer M, Ham L, Dapena I, Moutsouris K, Droustas K, van Dijk K, Frank L, Oellerich S, Melles GRJ. Efficacy of Descemet membrane endothelial keratoplasty (DMEK): Clinical outcome of 200 consecutive cases after a 'learning curve' of 25 cases. Arch Ophthalmol 2011;129:1435-43.
- ♦ Dapena I, Ham L, Droustas K, van Dijk K, Moutsouris K, Melles GRJ. Learning curve in Descemet's membrane endothelial keratoplasty. First series of 135 consecutive cases. Ophthalmology 2011;118:2147-54.
- ♦ Dirisamer M, Dapena I, Ham L, van Dijk K, Oganesyan O, Frank LE, van der Wees, Melles GRJ. Patterns of corneal endothelialization and corneal clearance after Descemet membrane endothelial keratoplasty for Fuchs endothelial dystrophy. Am J Ophthalmol 2011;152:543-55.
- ♦ Parker JS, Dirisamer M, Naveiras M, Ham L, van der Wees J, Melles GRJ. Endothelial cell density after Descemet membrane endothelial keratoplasty: 1-4 year follow-up. Am J Ophthalmol 2011;151:1107-1107.e2.
- ♦ Ham L, Dapena I, Moutsouris K, Balachandran C, Frank LE, van Dijk K, Melles GRJ. Refractive change and stability after Descemet membrane endothelial keratoplasty (DMEK): Corneal dehydration induces hyperopic shift not affecting lens power calculation. J Cataract Refract Surg. 2011;37:1455-64.
- ♦ Dapena I, Ham L, Netuková M, van der Wees J, Melles GRJ. Incidence of early allograft rejection following Descemet membrane endothelial keratoplasty (DMEK). Cornea 2011;30:1341-5.
- ♦ Moutsouris K, Dapena I, Ham L, Balachandran C, Oellerich S, Melles GRJ. Optical coherence tomography, Scheimpflug imaging and slit-lamp biomicroscopy in the early detection of graft detachment after Descemet membrane endothelial keratoplasty (DMEK). Cornea 2011;30:1369-75.
- ♦ Dirisamer M, Acis G, Dapena I, Ham L, Versteeg FFH, Melles GRJ. Secondary 'Thin DSEK' after long term graft failure in DLEK: A double transplanted cornea. Cornea 2011;30:828-31.
- ♦ Dapena I, Dapena L, Dirisamer M, Ham L, Melles GRJ. Agudeza visual y densidad de células endoteliales tras queratoplastia endotelial de membrana de Descemet (DMEK). Visual acuity and endothelial cell density following Descemet Membrane Endothelial Keratoplasty (DMEK). Arch Soc Esp Oftalmol 2011;86:395-401.
- ♦ Droustas K, Dapena I, Melles GRJ, Sekundo W. One corneal graft for two recipients: Preliminary results of Descemet Membrane Endothelial Keratoplasty (DMEK) at the Marburg University Eye Clinic. Greek Ann Ophthalmol 2011;21:17-21.
- ♦ van Dijk K, Dapena I, Moutsouris K, Ham L, Nieuwendaal CP, Melles GRJ: First DLEK series: 10-year follow-up. Ophthalmology 2011;118:424-424e3.
- ♦ Dapena I, Moutsouris K, Droustas K, Ham L, van Dijk K, Melles GRJ. Standardized 'no touch' technique for Descemet's membrane endothelial keratoplasty (DMEK). Arch Ophthalmol 2011;129:88-94.
- ♦ Ham L, Dapena L, Moutsouris K, Melles GRJ. Persistent corneal edema after descemetorhexis without corneal graft implantation in a case of Fuchs endothelial dystrophy. Cornea 2011;30:248-9.




Slit-lamp photographs, pachymetry maps and Scheimpflug images before and one and six months after 'Descemet membrane endothelial transferral' (DMET). With a 'free-floating' donor Descemet membrane (arrows) in the recipient anterior chamber, the host cornea has cleared at 3-6 months after surgery, with pachymetry values returning to normal.

'Descemet membrane endothelial transferral' (DMET) first type of treatment for corneal endothelial disorders without 'keratoplasty' DMEK to DMET: Is the concept of a 'keratoplasty' going to disappear?

Although corneal transplants have been performed for over a century, the phenomenon of 'spontaneous clearance' was first observed and documented at NIIOS in Rotterdam: a diseased cornea is able to clear without 'keratoplasty', i.e. without a surgical aim to restore the normal anatomy of the recipient cornea. According to our textbooks, such self-regenerative properties are impossible. The human corneal endothelium is notorious for its inability to recover by itself. For this reason, corneal transplant techniques have been developed, eye banks have been set up, and numerous scientific studies have been performed.

What will the future bring? Today, 'Descemet membrane endothelial keratoplasty' (DMEK) may be the most advanced keratoplasty procedure for the management of corneal endothelial disorders, through selective transplantation of an isolated donor Descemet membrane. In the newly designed procedure, 'Descemet membrane endothelial transferral' (DMET), the donor tissue is injected in the recipient anterior chamber, without any further surgical manipulation or positioning of the tissue. However, succesful DMET may require further modifications in tissue preparation technique as well as specialized organ culturing methods. Hence, if DMET proves to be a viable option, the roles of both the ophthalmologist and the eye bank may change in the future management of corneal endothelial disorders.

Specular microscopy of a cornea six months after DMET (right) shows re-endothelialisation of the recipient cornea. Surprisingly, DMET proved more effective in eyes with Fuchs endothelial dystrophy than in those with bullous keratopathy (left).





Amnitrans Eye Bank organized XXIVth meeting European Eye Bank Association

2012 EEBA meeting in Rotterdam

In January 2012, about 300 eye bank professionals and eye doctors visited the EEBA meeting that was held in the World Trade Center in Rotterdam, The Netherlands, with its focus on 'lamellar keratoplasty'. Both areas of expertise may anticipate significant changes in the approach of corneal disease. With the advent of several more advanced surgical techniques (DALK, DLEK, DSEK/ DSAEK, DMEK, DMET), which may give better clinical outcomes and fewer complications than conventional penetrating keratoplasty, a part of the surgical procedure may shift toward the eye bank. Furthermore, allocating the available tissue to the most eligible patient and more extensive quality controls would require more complex eye bank logistics.

Furthermore, the demand for donor tissue may change with the introduction of new surgical techniques. After UV-crosslinking, most patients may never reach the point where they require a corneal transplantation. If DMET would also prove successful, the number of donor tissues required for treatment of Fuchs endothelial dystrophy could also diminish. Since both these corneal disorders represent the vast majority of the indications for a corneal transplant in Europe, these shifts in preferred treatment methods could have a major impact on future tissue demands.





Mr. Pereira da Silva

A patient tells his tale...

“Back to business!”

Mr. Pereira da Silva, 47-years old, is chief executive director of Renova, a paper company based in Portugal. A few years ago, he was diagnosed with Fuchs endothelial dystrophy.

What was your life like before the operation? How did you manage?

“Fortunately, I have the ability to adapt myself to difficult situations. I actually did not realize how bad my eyes were, although I was using a big computer screen and could not read signs outdoors, or in the airport to check the flight times. I always travel with lots of people and I have my private driver, so I was able to compensate for my handicap. It was, however, a problem that I, as a managing director, could not read the presentation slides at meetings, and just had to guess what was being presented.”

Why did you choose a treatment at Melles Cornea Clinic in Rotterdam?

“For my company in Portugal, I travel back and forth to the US on a regular basis. While surfing the internet, I read about the interest taken in Fuchs endothelial dystrophy by one famous American university. So I visited that eye clinic to have my eyes examined. They diagnosed me with Fuchs, which did not come as a surprise since my aunt and my father both have been suffering from Fuchs as well. In the US and in Portugal, the doctors wanted to wait on a corneal transplant, probably because the results after penetrating keratoplasty were unpredictable and sometimes disappointing. But I just could not permit myself to be visually disabled in my work, with all responsibilities that come with it. While participating in an interest group for Fuchs patients on the internet, bit by bit, I learned a lot about the old transplantation technique and its recovery process. I thought to myself, “there must be something better.” So I vigorously searched the internet and eventually found myself reading every paper I could find written by Dr. Melles and his team about this new method of his. I was the first person from the entire internet group to choose for a DMEK in Rotterdam.”

How was the surgery?

“Before the operation, I was really stressed. But I came well prepared after reading everything there was to know about corneal transplantation. The atmosphere was rather relaxed and I felt comfortable. I had some pain after the procedure, but that was to be expected, and I had my painkillers standing by.”

How was the postoperative course and your recovery?

“After only 4 days, I saw better than ever before: It was only at this time that I realized how bad my eyesight had been before. It has been phenomenal. Three months after my first operation, I was operated on my second eye.”

What is your general impression of Melles Cornea Clinic Rotterdam?

“I am recommending the clinic to everyone. That says it all! On the internet, I am very actively informing the patient interest groups and promoting the clinic and all of its procedures!”

miESC
minimally
invasive
Eye
Surgery
Congress

St. Gallen, Switzerland od@ag
ophthalmic
diagnosis
at
a
glance

Save the Date

Thursday April 25th, 2013
Friday April 26th, 2013
Saturday April 27th, 2013

www.miesc.com

2nd minimally invasive Eye Surgery Congress

Two-day advanced keratoplasty wetlab courses in Rotterdam

- Deep anterior lamellar keratoplasty (DALK)
- Descemet membrane endothelial keratoplasty (DMEK)

Each course is scheduled on a Tuesday/Wednesday. On Tuesdays, the course participants join live surgery sessions; on Wednesday, various techniques are practised during educational wetlab sessions and patient demonstrations.

See www.nios.com for application form and update.

- ☞ DALK/DMEK: March 13/14, 2012
- ☞ DALK/DMEK: April 17/18, 2012
- ☞ DALK/DMEK: June 5/6, 2012
- ☞ DALK/DMEK: September 4/5, 2012
- ☞ DALK/DMEK: November 13/14, 2012

