

NIIOS Newsletter

Netherlands Institute for Innovative Ocular Surgery

Laan op Zuid 88
3071 AA Rotterdam - The Netherlands
Tel +31 10 297 4444 - Fax +31 10 297 4440
info@nijos.com - www.nijos.com



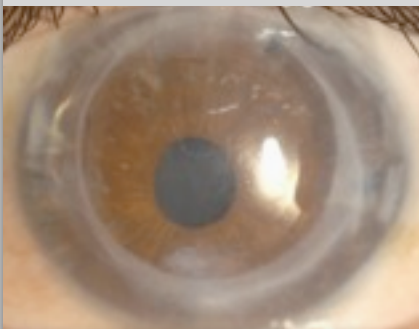
PAGE 2
DR. MELLES RECEIVES
'BARRAQUER MEMBERSHIP
OF HONOR'

PAGE 3
NIIOS EYE SCENE
INVESTIGATION

PAGE 3
200% VISUAL ACUITY
AFTER DMEK

PAGE 4
DMEK SURGICAL VIDEO
WITH MUSIC

PAGE 4
PATIENT STORY:
BEFORE & AFTER DMEK



REFERRALS TO MELLES CORNEA CLINIC ROTTERDAM

For referrals to Melles Cornea Clinic Rotterdam, please use the referral form enclosed. The form can also be downloaded from www.nijos.com. Please fax the referral form to +31 10 297 4440 and one of our international secretaries will make further arrangements.

If you want to contact us by e-mail, please contact Ms Kim Herders at herders@nijos.com.

Growing interest among DSEK/DSAEK patients with subnormal visual acuity to have a re-operation with DMEK

Should all DSEK/DSAEK patients now be re-operated?


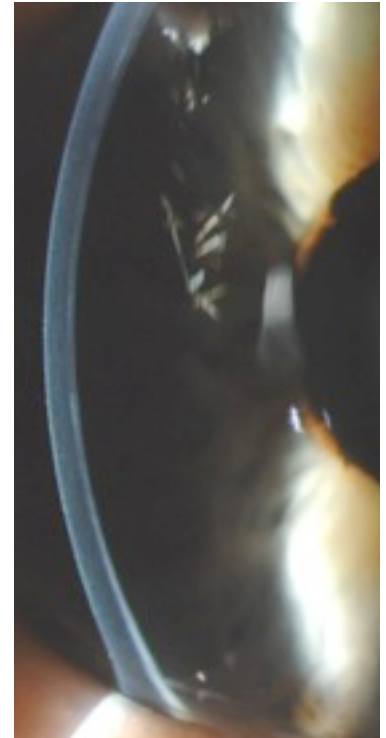
Since 1998, NIIOS introduced various concepts for endothelial keratoplasty for management of corneal endothelial disorders. A first concept was initially popularized as 'deep lamellar endothelial keratoplasty' (DLEK). A second concept in which an unsutured posterior graft is positioned onto the recipient posterior stroma after a descemetorhexis, i.e. 'Descemet stripping (automated) endothelial keratoplasty' (DSEK/DSAEK), has been adapted worldwide. More recently, a third concept was described that allows for selective transplantation of a donor Descemet membrane, now referred to as Descemet membrane endothelial keratoplasty (DMEK).

Compared to conventional penetrating keratoplasty, the visual acuity after DSEK/DSAEK may be better, on average 20/40 (0.5) as reported by most clinical studies. However, only a few cases may reach a normal visual acuity of $\geq 20/25$ (≥ 0.8). The visual outcome after penetrating keratoplasty and DSEK/DSAEK may be significantly lower than with DMEK, in which a vast majority of eyes may reach $\geq 20/25$ (≥ 0.8). In the first group of 100 DMEK patients in our clinic, 74% obtained a visual acuity of 20/25 (0.8) or better, six months after surgery. Apparently, the optical quality of a cornea is better restored by using a thin Descemet graft rather than a thicker DSEK/DSAEK graft.

Unexpectedly, the difference in visual outcome between DSEK/DSAEK and DMEK now seems to pose an interesting ethical dilemma. About four to five years ago, DMEK became our preferred method in the treatment of corneal endothelial disorders. Hence, patients who initially had received a DSEK/DSAEK graft in one eye, were offered a DMEK graft in the other eye. Without exception, the DMEK eye is preferred over the DSEK/DSAEK eye, and sometimes the DSEK/DSAEK graft is felt to interfere with binocular vision. Furthermore, patient education - through the internet, special interest groups, or merely chatting in the waiting room - may also fuel requests for re-transplantation with a secondary DMEK after initial DSEK/DSAEK.

At first glance, re-operation may only be indicated in cases with good visual potential, but disappointing visual outcome. For example the case presented here: a visual acuity of 20/100 (0.2) could

Continued on page 2



Slit-lamp photographs of an eye 1 year after DSEK and 1 month after DMEK. Best corrected visual acuity improved from 20/100 (0.2) to 20/25 (0.8).

Cornea & Research fellows 2010



Konstantinos Droutsas



Martin Dirisamer

NIIOS scientific publications 2010

- ♦ Lie JT, Groeneveld EA, Ham L, van der Wees J, Melles GRJ. More efficient use of donor corneal tissue with Descemet membrane endothelial keratoplasty (DMEK): Two lamellar keratoplasty procedures with one donor cornea. Br J Ophthalmol. In press.
- ♦ Lie JT, Droutsas K, Ham L, Dapena I, Ververs B, Otten H, van der Wees J, Melles GRJ. Isolated Bowman layer transplantation to manage persistent subepithelial haze after excimer laser surface ablation. J Cataract Refract Surg. 2010;36:1036-41.
- ♦ Ham L, Dapena I, van der Wees J, Melles GRJ. Secondary DMEK for low visual outcome after DSEK: Donor posterior stroma may limit visual acuity in endothelial keratoplasty. Cornea. In press.
- ♦ Dapena I, Ham L, van Luijk C, van der Wees J, Melles GRJ. Back-up procedure for graft failure in Descemet membrane endothelial keratoplasty (DMEK). Br J Ophthalmol. Accepted.
- ♦ Moutsouris K, Ham L, Dapena I, van der Wees J, Melles GRJ. Radial graft contraction may relate to subnormal visual acuity in Descemet stripping (automated) endothelial keratoplasty. Br J Ophthalmol. 2010;94:951-3.
- ♦ Balachandran C, Ham L, Dapena I, van der Wees J, Melles GRJ. Reply to comment by Price et al on 'Spontaneous corneal clearance despite graft detachment after DMEK'. Am J Ophthalmol. 2010;149:174-5.
- ♦ Balachandran C, Ham L, Dapena I, van der Wees J, Melles GRJ. Reply to comment by Stewart et al on 'Spontaneous corneal clearance despite graft detachment after DMEK'. Am J Ophthalmol. 2010;149:683-4.
- ♦ Lie JT, Birbal R, Ham L, van der Wees J, Melles GRJ. Reply to comment by Athanasiadis I et al: Donor tissue preparation for DMEK. J Cataract Refract Surg. 2009;35:408.
- ♦ Dapena I, Moutsouris K, Droutsas K, Ham L, van Dijk K, Melles GRJ. Standardized 'no touch' technique for Descemet membrane endothelial keratoplasty (DMEK): Controlled donor tissue implantation, orientation, unrolling, centering, appositioning and fixation. Arch Ophthalmol. Accepted.
- ♦ Ham L, Dapena I, Moutsouris K, Melles GRJ. Persistent corneal edema after descemetorhexis without corneal graft implantation in a case of Fuchs endothelial dystrophy. Cornea. Accepted.
- ♦ Dapena I, Ham L, Moutsouris K, Melles GRJ. Incidence of recipient Descemet membrane remnants at the donor-to-stromal interface after descemetorhexis in endothelial keratoplasty. Br J Ophthalmol. Accepted.
- ♦ Dapena I, Moutsouris M, Ham L, Melles GRJ. Graft detachment rate in Descemet membrane endothelial keratoplasty (DMEK). Ophthalmology. 2010;117:847.
- ♦ Droutsas K, Ham L, Dapena I, Geerling G, Oellerich S, Melles GRJ. Visus nach Descemet-Membran Endothelkeratoplastik (DMEK). Ergebnisse der ersten 100 Eingriffe bei Fuchs'scher Endotheldystrophie. Klin Monatsbl Augenheilkd. 2010;227:467-77.
- ♦ Ham L, Dapena I, van der Wees J, Melles GRJ. Endothelial cell density after Descemet membrane endothelial keratoplasty (DMEK). 1-3 year follow-up. Am J Ophthalmol. 2010;149:1016-7.

Continued from page 1

be improved to 20/25 (0.8) by replacing a DSEK graft by a secondary DMEK graft. However, what lower limit can be justified? Cataract surgery is commonly performed in eyes with a visual acuity of 20/40 (0.5). If so, why would this visual acuity level after an initial DSEK/DSAEK not be an indication for a secondary DMEK? Since DMEK enables eye banks to use one donor cornea for two patients (Descemet graft in DMEK and the anterior cornea for a deep anterior lamellar keratoplasty), what arguments remain to deny a patient a secondary DMEK?

In our experience, improving clinical outcomes in endothelial keratoplasty seem to quickly change patient expectation on visual outcome. Since further development of endothelial keratoplasty may be associated with earlier intervention as well as a different use of donor corneas, a more flexible clinical approach toward corneal endothelial disease and eye bank logistics may be warranted.

Ham L, Dapena I, van der Wees J, Melles GRJ. Secondary DMEK for low visual outcome after DSEK: Donor posterior stroma may limit visual acuity in endothelial keratoplasty. Cornea. In press.

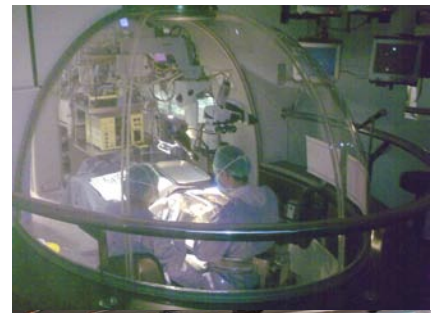
Gurus of lamellar keratoplasty start with DMEK

Dr. Melles receives 'Barraquer membership of honor'

'El Instituto Barraquer', run by a dynasty of ophthalmologists, of whom the first was born in 1852. In the last century, the Barraquers have made a huge contribution to modern corneal surgery. Many of the technical concepts known today, were already developed in some form by José Ignacio Barraquer Moner (†1998) and his brother Joaquín Barraquer Moner. The latter is still actively participating in the family clinic in Barcelona.

The famous Spanish eye-clinic, built in the 1930s on an open piece of land at the time, has now 'grown into' the city center. The building itself may already be regarded as a piece of art, reflecting the creativity used inside to perform surgery. Every room is well designed, with ground breaking designs like the reversed-cockpit-like window behind the surgeon, allowing observers to watch the surgery from closeby while the sterile field is maintained, or the carousel that swings the doctor and his slit-lamp through four patient examination rooms.

Although endothelial transplants underneath a free-handed dissected corneal flap were performed by the Barraquers in the 1960s (as did Dr. Charles Tillett in the United States), endothelial keratoplasty as we know it today was not pursued, probably because at the time the development of refractive procedures had more priority. However, receiving the 'membership of honor' from 'the Newton' of corneal surgery, professor Joaquín Barraquer, felt as a most prestigious recognition of the work performed on the concept of endothelial keratoplasty by the entire NIIOS team.



The dome-shaped operation theatre (above) and the award handed over to Dr. Melles by professor Joaquín Barraquer.

★ Win a free NIIOS wetlab instruction course in Rotterdam ★

NIIOS eye scene investigation

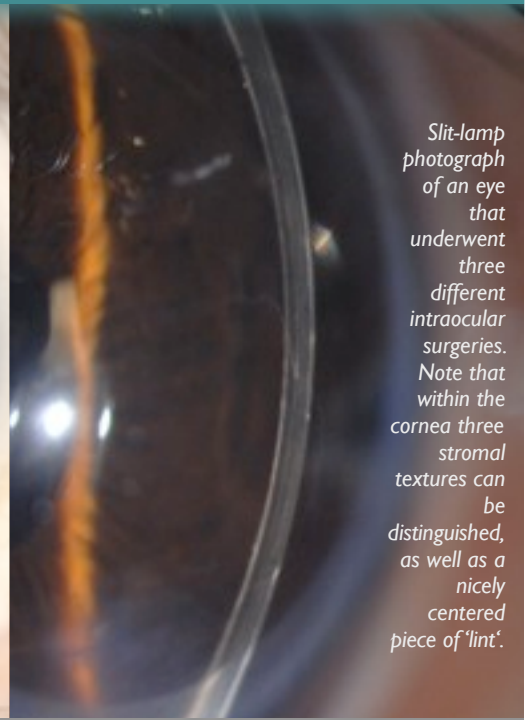
There is more between heaven and earth. At least in The Netherlands. Fascinating stories, exciting clinical observations, findings poorly understood, as well as events that, according to textbooks, are not supposed to occur. These 'eye-openers' may quickly be rationalized and may find themselves less than welcome in peer-reviewed scientific journals. They simply do not fit in.

Nevertheless, issues that question expert opinions, well established concepts and accepted 'proof of principles', that range from clinical challenges to almost ghost stories, may also deserve attention. To better accommodate the scientific orphans, 'NIIOS eye scene investigation' was created.

This 31-year-old patient underwent three surgeries in his left eye, in respectively 2002, 2003 and 2009. Given this extensive amount of information, could you answer the following questions?

- ☞ Which surgeries were performed in the left eye of this patient?
- ☞ What visual acuity level was obtained at one month after the last surgery?
- ☞ Which consequences may this finding have for corneal transplant surgery?

Please submit your answers to these questions through www.nios.com → **NIIOS Quiz**. Submissions with correct answers are eligible to win a NIIOS wetlab instruction course free of charge.



Slit-lamp photograph of an eye that underwent three different intraocular surgeries. Note that within the cornea three stromal textures can be distinguished, as well as a nicely centered piece of 'lint'.

Answers NIIOS eye scene investigation March 2010:

Winner: *Paulo E.C. Dantas, Sorocaba Eye Hospital, University São Paulo, Brazil*

200% visual acuity after DMEK

- ☞ *What happened to the left eye?*
A DMEK surgery was performed for Fuchs endothelial dystrophy.
- ☞ *What is this patient trying to point out to you?*
His visual acuity was 20/10 (2.0) after DMEK (at 6 months).

☞ *What consequences may this finding have for corneal transplant surgery?*

Today, about 75% of patients reach a visual acuity of $\geq 20/25$ (≥ 0.8) at six months (and about 95% $\geq 20/40$ (≥ 0.5)), with an endothelial cell density of about 1800 cells/mm².

Interestingly, a substantial number of DMEK patients in the NIIOS series reach a visual acuity level that exceeds 20/20 (1.0), i.e. >100%. A visual acuity of 20/10 (2.0) may already be considered exceptional for a 'normal' eye, but when such a visual acuity level can be reached after DMEK, it may indicate that the optical quality of the transplanted cornea may approach that of a 'virgin' cornea, i.e., a cornea that has not been operated before. In contrast to DSEK/DSAEK, in which posterior (donor) stroma is added to the overall anatomy of the cornea, no extra tissue structures are added in DMEK. Hence, our findings may further support the hypothesis that an 'anatomical' corneal restoration with DMEK provides the best possible optical function, and therefore, (near) complete visual recovery. If so, DMEK may have potential to become a preferred treatment method.

Two-day advanced keratoplasty wetlab instruction courses 2010/2011


- Deep anterior lamellar keratoplasty (DALK)
- Descemet stripping endothelial keratoplasty (DSEK)
- Descemet membrane endothelial keratoplasty (DMEK)

- ☞ DALK/DMEK: October 12/13, 2010
- ☞ DALK/DMEK: November 16/17, 2010
- ☞ DALK/DMEK: February 15/16, 2011
- ☞ DALK/DMEK: April 12/13, 2011
- ☞ DALK/DMEK: June 7/8, 2011

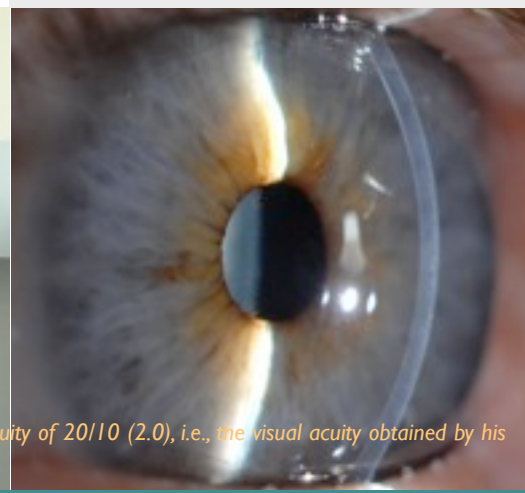
Each course is scheduled on a Tuesday/Wednesday. On Tuesday, the course participants join live surgery sessions; on Wednesday, various techniques are practised during educational wetlab sessions.

Level: Advanced - Corneal surgeons and senior eyebank technicians.

See www.nios.com for application form and update.




Mr Van der Ploeg points to the lower line on the chart, representing a Snellen visual acuity of 20/10 (2.0), i.e., the visual acuity obtained by his left eye (right) six months after 'Descemet membrane endothelial keratoplasty' (DMEK).





The music for the DMEK surgical video was recorded by the 'Artes-Streichquartett' in the 'Christuskirche' in Recklinghausen, Germany. The patient, Mr Haunhorst, sits on the far left.



Patient features visually (as a patient) and audibly (as a violinist)

DMEK surgical video with music

Taping a DMEK surgery is one thing, but putting the right music to it may be just as important. Such music did not yet exist and one also needs musicians to record it.

The need to fill-in this niche in the history of endothelial keratoplasty brought patient (and violinist) and doctor (and amateur composer) together in producing a DMEK surgical video. The eye of the patient features on the video. The patient also recorded the dedicated music with the 'Artes-Streichquartett' in Recklinghausen.

The DMEK surgical video is available at the NIIOS homepage www.nios.com (righthand column); and on DVD via an e-mail to dekort@nios.com.

Concertmaster 'Bergische Symphoniker' couldn't read the music Patient story: before & after DMEK

In 2009, Mr Haunhorst underwent a DMEK surgery for treatment of a Fuchs endothelial dystrophy. While being the first violinist of a symphonic orchestra in Germany, he developed a second career as an 'eye-mannequin', now featuring on a NIIOS DVD.

How was life before the surgery?

For years, I knew that I had a classic Fuchs endothelial dystrophy. It became progressively worse, which initially brought me some advantages. Being already poorly talented in cleaning the dishes, my wife relieved me from such homely duties, because the results were supposedly less than acceptable. In my work, however, I really had to train myself to distinguish the 'sharps', 'flats' and 'natural signs' from each other. I hardly saw the difference anymore due to loss of contrast.

Why did you choose for a treatment in the Melles Cornea Clinic?

In Germany you have to wait until your visual acuity drops below 30%, before you are eligible for surgery. That was rather difficult to cope with, since such bad vision seems too low for musicians in an orchestra, who have to quickly read the music. I decided to keep my ears open, not only for playing in the same key as my fellow-musicians, but also to find out about the latest developments in corneal transplantation surgery. Luckily I ran into a knowledgeable ophthalmologist in Ahaus, who personally knew Dr. Melles, and has then referred me to Rotterdam.

How was the surgery?

I was a bit afraid of course, but, well, that's normal. I didn't realize that during the surgery, you can't see with the eye that is being operated. You then start to think "I am going to witness the whole thing and somebody will show up with a big needle..." But after the local anesthesia, the eye goes black as if you turn off the television. You sense that something is being done, and just because you don't feel much pain, you start to ask yourself whether "this is it" or does the real pain just have to come?

And while contemplating about the possibility of being in pain, I realized that it was a bit cold in the operation theatre. You have to lay still and a delicate air flow just seemed to be aimed at my family jewels. That gave me something else to worry about. This now may be complaining at a meta-level. The whole experience of having the surgery was actually not intimidating at all. Also, it struck me that so much manual work was involved. It added to my admiration for what was being achieved. The skills and everything at ease.

How did you experience the aftermath?

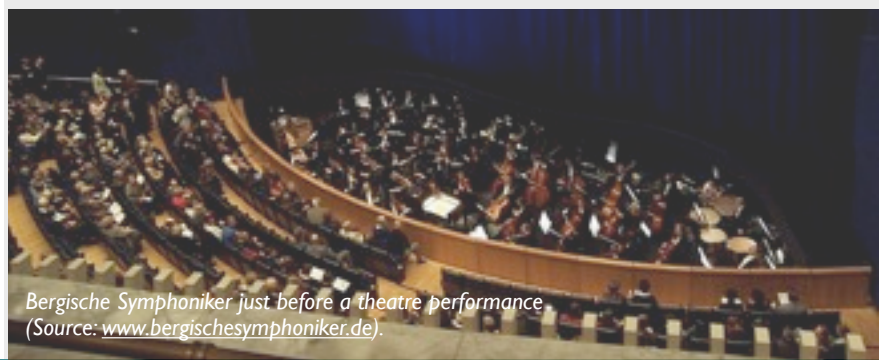
Every morning I thought "The transplant does not work anymore!" But in the evening hours it was then better again, and after a week it stabilized...

Did things improve by having the DMEK surgery?

Rather stunning, since the colors are much clearer. As if the whole world was put into the dishwasher. It is almost too bad that you get used to it so quickly again, but I still have my other eye to compare. It is really a gift from heaven. My limited skills for cleaning at home somehow persisted, but reading music is no problem anymore.

What is your experience with the Cornea Clinic Rotterdam?

Amazingly wonderful. Being German, you expect a huge hospital with a line of doctors who glance at you briefly while mumbling and pitifully shaking their heads. Instead, there is little hierarchy, major achievement and a super team spirit. Everybody works towards the same goal, and they like doing it. Dr. Melles gives you a certain peace of mind, an artist, and being a musician myself, I really appreciated that.



Bergische Symphoniker just before a theatre performance
(Source: www.bergischesymphoniker.de).