

NIIOS Newsletter

Netherlands Institute for Innovative Ocular Surgery

Laan op Zuid 88
3071 AA Rotterdam - The Netherlands
Tel +31 10 297 4444 - Fax +31 10 297 4440
info@niios.com - www.niios.com



PAGE 2
DR MELLES THE FIRST TO RECEIVE ZIRM AWARD

PAGE 3
NIIOS EYE SCENE INVESTIGATION

PAGE 3
CLINICAL OUTCOME FIRST 100 DMEK CASES

PAGE 4
TEN YEARS AFTER THE FIRST SUCCESSFUL SERIES OF ENDOTHELIAL KERATOPLASTY



REFERRALS TO MELLES CORNEA CLINIC ROTTERDAM

For referrals to Melles Cornea Clinic Rotterdam, please use the referral form enclosed. The form can also be downloaded from www.niios.com. Please fax the referral form to +31 10 297 4440 and one of our international secretaries will make further arrangements.

If you want to contact us by e-mail, please contact Ms Kim Herders at herders@niios.com.

New concept in lamellar keratoplasty to manage anterior stromal opacities and complicated epithelial wound healing

Isolated Bowman layer transplantation

Bowman layer related corneal disorders, ie 'abnormal' epithelial-stromal interaction in the presence or absence of Bowman layer, may be relatively frequent in hereditary corneal dystrophies, persistent epithelial defects or following excimer laser photoablation. Although the pathophysiology may vary, current treatment options may sometimes further compromise the normal anatomical structure. For example, the development of an anterior stromal haze after excimer surface ablation, that may result from an abnormal wound healing response in the absence of a Bowman layer, may be managed by re-ablation with application of mitomycin 0.02% to restore corneal transparency. However, this approach may not eliminate the most probable cause of haze development, that is the lack of an anatomical Bowman layer. Furthermore, recurrent or persistent haze non-responsive to re-ablation may be difficult to manage, and may eventually require a deep anterior lamellar keratoplasty to avoid keratectasia and/or to restore an optically clear cornea.

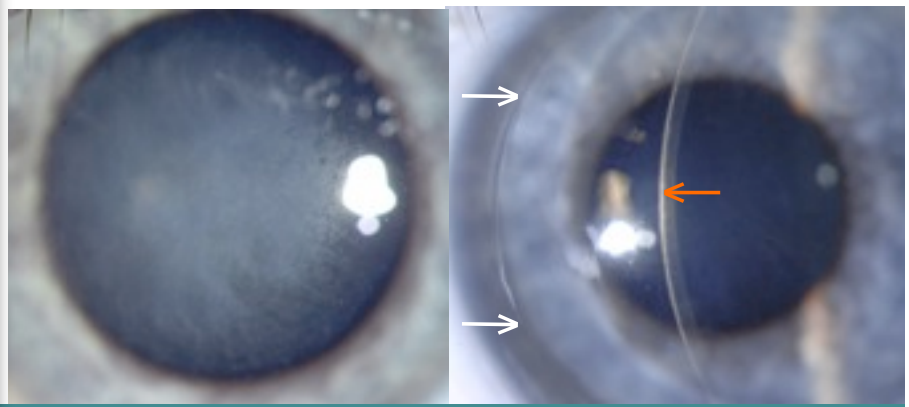
Since haze development is rare or even non-existent after traumatic or iatrogenic corneal abrasions, it may be hypothesized that a subepithelial stromal scar induced by an epithelial-stromal wound healing response does not occur in the presence of the anatomical Bowman layer. For that reason, the NIIOS developed a new surgical concept, that allows for the excision of a stromal superficial stromal scar with a femtosecond laser, followed by the transplantation of an unsutured, isolated donor Bowman layer onto a recipient stromal bed, to restore and maintain an optically clear cornea. As part of the procedure, a sclera-supported hard contact lens with complete corneal clearance may be fitted to further improve the visual acuity.

Isolated Bowman layer transplantation may prove to have advantages over more invasive treatment options, like penetrating keratoplasty or deep anterior lamellar keratoplasty (DALK):


- ◆ The procedure may be easier to perform, while requiring less surgical time.
- ◆ The risk of intraoperative complications may be lower, because it is a completely 'extraocular' procedure.
- ◆ The risk of iatrogenic complications may be reduced: Suture-related problems are eliminated since no sutures are used, and wound dehiscence can not occur.
- ◆ The risk of an allograft rejection may be minimized: because Bowman layer does not contain cellular components, an immune response can not occur.
- ◆ The procedure may need less aftercare: suture removal is not required, all medication can quickly be tapered, and a contact lens is already fitted before the surgery.

Continued on page 2

Slit-lamp photographs of an eye before and one week after isolated Bowman layer transplantation for grade 4+ haze after excimer laser photoablation. The Bowman graft shows as a faint white line (orange arrow). The white arrows point to the rim of the host bed, created after dissection of the scar with a femtosecond laser.



Cornea & Research fellows 2009 / 2010



Kyros Moutsouris

Konstantinos Droutsas

NIIOS scientific publications 2009 / 2010

- ♦ Dapena I, Moutsouris M, Ham L, Melles GRJ. Graft detachment rate in Descemet membrane endothelial keratoplasty (DMEK). *Ophthalmology*. In press.
- ♦ Lie JT, Groeneveld EA, Ham L, van der Wees J, Melles GRJ. More efficient use of donor corneal tissue with Descemet membrane endothelial keratoplasty (DMEK): Two lamellar keratoplasty procedures with one donor cornea. *Br J Ophthalmol*. Accepted.
- ♦ Lie JT, Droutsas K, Ham L, Dapena I, Ververs B, Otten H, van der Wees J, Melles GRJ. Isolated Bowman layer transplantation to manage persistent subepithelial haze after excimer laser surface ablation. *J Cataract Refract Surg*. Accepted.
- ♦ Ham L, Dapena I, van der Wees J, Melles GRJ. Secondary DMEK for low visual outcome after DSEK: Donor posterior stroma may limit visual acuity in endothelial keratoplasty. *Cornea*. Accepted.
- ♦ Dapena I, Ham L, van Luijk C, van der Wees J, Melles GRJ. Back-up procedure for graft failure in Descemet membrane endothelial keratoplasty (DMEK). *Br J Ophthalmol*. Accepted.
- ♦ Moutsouris K, Ham L, Dapena I, van der Wees J, Melles GRJ. Radial graft contraction may relate to subnormal visual acuity in Descemet stripping (automated) endothelial keratoplasty. *Br J Ophthalmol*. Accepted.
- ♦ Balachandran C, Ham L, Dapena I, van der Wees J, Melles GRJ. Reply to comment by Price et al on 'Spontaneous clearance despite graft detachment after DMEK'. *Am J Ophthalmol*. Accepted.
- ♦ Balachandran C, Ham L, Dapena I, van der Wees J, Melles GRJ. Reply to comment by Stewart et al on 'Spontaneous clearance despite graft detachment after DMEK' *Am J Ophthalmol*. Accepted.
- ♦ Lie JT, Birbal R, Ham L, van der Wees J, Melles GRJ. Reply: Thin DSEK versus DMEK. *J Cataract Refract Surg*. In press.
- ♦ Nieuwendaal CP, van Velthoven MEJ, Bialosterski C, van der Meulen IJE, Lapid-Gortzak R, Melles GRJ, Verbraak FD. Thickness measurements of donor posterior discs after Descemet-stripping endothelial keratoplasty with anterior segment optical coherence tomography. *Cornea* 2009;28:298-303.
- ♦ Ham L, Balachandran C, Verschoor AM, van der Wees J, Melles GRJ. Visual rehabilitation rate after isolated Descemet membrane transplantation: Descemet membrane endothelial keratoplasty. *Arch Ophthalmol*. 2009;127:252-5.
- ♦ Ham L, van Luijk C, Dapena I, Wong TH, Birbal R, van der Wees J, Melles GRJ. Endothelial cell density after Descemet membrane endothelial keratoplasty (DMEK): 1- to 2-year follow-up. *Am J Ophthalmol*. 2009;148:521-7.
- ♦ Balachandran C, Ham L, Birbal R, Wong TH, van der Wees J, Melles GRJ. Simple technique for graft insertion in Descemet-stripping (automated) endothelial keratoplasty using a 30-gauge needle. *J Cataract Refract Surg*. 2009;35:625-8.
- ♦ Ham L, Dapena I, van Luijk C, van der Wees J, Melles GRJ. Descemet membrane endothelial keratoplasty (DMEK) for Fuchs endothelial dystrophy: review of the first 50 consecutive cases. *Eye*. 2009;23:1990-8.
- ♦ Dapena I, Ham L, Melles GRJ. Endothelial keratoplasty: DSEK/DSAEK or DMEK - the thinner the better? *Curr Opin Ophthalmol*. 2009;20:299-307.
- ♦ Balachandran C, Ham L, Verschoor CA, Ong TS, van der Wees J, Melles GRJ. Spontaneous corneal clearance despite graft detachment in Descemet membrane endothelial Keratoplasty (DMEK). *Am J Ophthalmol*. 2009;148:227-34.
- ♦ Dapena I, Ham L, Tabak S, Balachandran C, Melles GRJ. Phacoemulsification after Descemet membrane endothelial keratoplasty. *J Cataract Refract Surg*. 2009;35:1314-5.
- ♦ Dapena I, Ham L, Lie JT, van der Wees J, Melles GRJ. Queratoplastia endotelial de membrana de Descemet (DMEK): Resultados a dos años. *Arch Soc Esp Oftalmol*. 2009;84:237-44.



Dr. Mathias Zirm memorized his grandfather's pioneering scientific work, which formed the start of clinical corneal transplantation, embodied by the 'Zirm award'.

Award named after the first ophthalmologist to perform a corneal transplant, handed over by his grandson

Dr. Melles the first to receive Zirm award

In 1905, Dr. Eduard Zirm was the first to perform a successful full-thickness corneal transplant in a living human eye, in Olomouc in (Czechoslovakia. A patient with a bilateral leukemia following a chemical burn injury, received a donor cornea from an 11-year old donor.

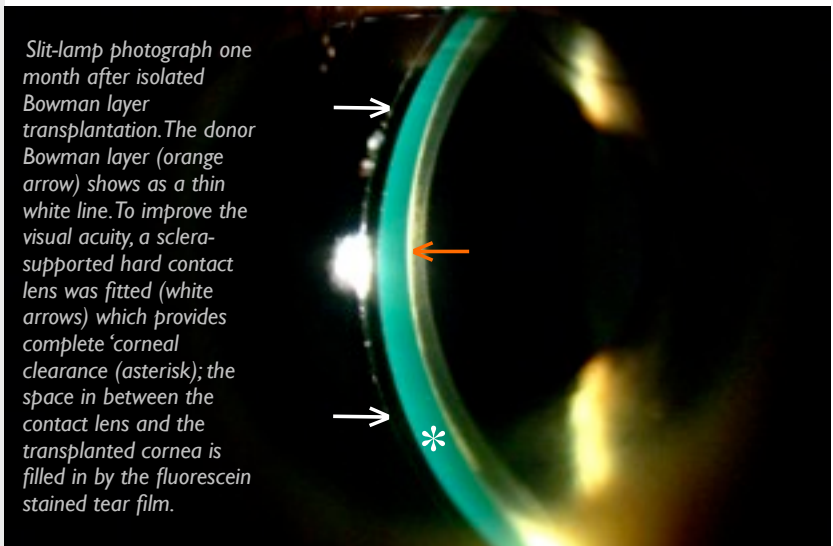
With a 'von Hippel trephine' (developed by Dr. Arthur von Hippel, who performed the first lamellar keratoplasty in 1888), a 5 mm corneal button was excised and transplanted, and fixated with 'overlying' sutures. The surgical milestone followed earlier attempts initiated for over a century.

At the Czech Society of Cataract and Refractive surgery meeting in Prague on December 10/11 2009, organized by prof. Pavel Kuchynka and Dr. Pavel Studeny, Dr. Zirm's grandson, Univ.-Prof. Dr. Mathias Zirm, a well-known ophthalmologist in Austria, honored Dr. Melles with the first Zirm award for more recent developments in (albeit lamellar) corneal transplantation surgery.

Continued from page 1

- ♦ Donor tissue availability may be better, since a donor Bowman layer can be dissected from corneas unsuitable for penetrating or (deep) anterior lamellar keratoplasty, or 'left over' anterior corneal caps following dissection of a DSEK/ DSAEK endothelial transplant.
- ♦ Since only a superficial scar is removed, the ocular integrity is largely preserved.
- ♦ If unsuccessful, a more invasive (penetrating or lamellar) keratoplasty procedure can be performed.
- ♦ Compared to penetrating keratoplasty or DALK, the visual recovery time may be much faster. Interface scarring may be unlikely to occur, so that near complete visual recovery may be anticipated. Hence, isolated Bowman layer transplantation may become a realistic treatment option in eyes with recurrent or persistent subepithelial haze causing substantial contrast sensitivity loss or glare, but with a normal visual potential.

Lie JT, Droutsas K, Ham L, Dapena I, Ververs B, Otten H, van der Wees J, Melles GRJ. Isolated Bowman layer transplantation to manage persistent subepithelial haze after excimer laser surface ablation. *J Cataract Refract Surg*. In press.



Slit-lamp photograph one month after isolated Bowman layer transplantation. The donor Bowman layer (orange arrow) shows as a thin white line. To improve the visual acuity, a sclera-supported hard contact lens was fitted (white arrows) which provides complete 'corneal clearance' (asterisk); the space in between the contact lens and the transplanted cornea is filled in by the fluorescein stained tear film.

★ Win a free NIIOS wetlab instruction course in Rotterdam ★
NIIOS eye scene investigation

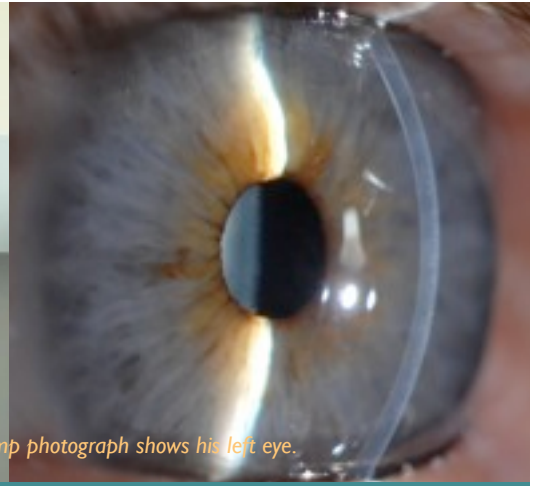

There is more between heaven and earth. At least in The Netherlands. Fascinating stories, exciting clinical observations, findings poorly understood, as well as events that, according to textbooks, are not supposed to occur. These 'eye-openers' may quickly be rationalized and may find themselves less than welcome in peer-reviewed scientific journals. They simply do not fit in.

Nevertheless, issues that question expert opinions, well-established concepts, and accepted 'proof of principles', that range from clinical challenges to almost ghost stories, may also deserve attention. To better accommodate the scientific orphans, the 'NIIOS eye scene investigation' was created.

This 48-year old patient had a corneal transplant in the 1990s, complicated by an endophthalmitis and eventually followed by enucleation of the right eye. Given this extensive information, could you answer the following questions?

- ☞ What happened to the left eye?
- ☞ What is this patient trying to point out to you?
- ☞ What consequences may this finding have for corneal transplant surgery?

Please submit your answers to these questions through www.niios.com → NIIOS Quiz. Submissions with correct answers are eligible to win a NIIOS wetlab instruction course free of charge.



Mr van der Ploeg points out the answers to the questions of the NIIOS Quiz. The slit-lamp photograph shows his left eye.

Descemet membrane endothelial keratoplasty (DMEK)
 to become successor DSEK/DSAEK
Clinical outcome first 100 DMEK cases

After the introduction of the concept for 'deep lamellar endothelial keratoplasty' (DLEK) and Descemet stripping endothelial keratoplasty (DSEK/DSAEK) for treatment of corneal endothelial disorders, the NIIOS recently described a technique for isolated donor Descemet membrane transplantation: 'Descemet membrane endothelial keratoplasty' (DMEK).

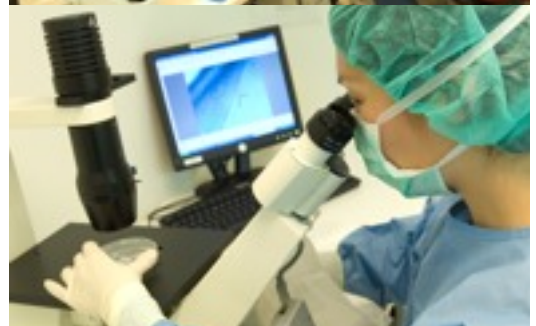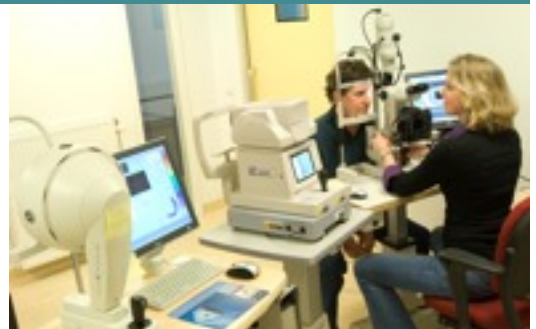Recently the first 100 consecutive eyes that underwent DMEK for Fuchs endothelial dystrophy were evaluated. In eyes with a functional graft and normal visual potential (n=81), the BCVA was $\geq 20/40$ (≥ 0.5) in 79% after one month, 94% after three months, and 96% after six months; and $\geq 20/25$ (≥ 0.8) in respectively 54%, 64%, and 74%. Endothelial cell densities averaged 2630 (± 190) cells/mm² before, and 1800 (± 540) cells/mm² at six months (n=76). In 16 eyes, a secondary DSEK was performed.

At the NIIOS, the clinical outcome of DMEK may still be improving through ongoing R&D projects on tissue harvesting, dissection and preservation methods, the refinement of the surgical technique and the instruments, as well as meticulous follow-up measurements of all patients at regular time intervals. Already a vast majority of patients obtains a quick and nearly complete visual rehabilitation within the first months after surgery.

**DMEK for
 Fuchs endothelial dystrophy:
 Within 1-6 months
 74% BVCA $\geq 20/25$ (≥ 0.8)**

Endothelial cell survival may be similar to that after DLEK and DSEK/DSAEK, and early graft detachment in 2-5% of cases, may be the main complication in this first series of DMEK surgeries.

Ham L, Dapena I, van Luijk C, van der Wees J, Melles GRJ. Descemet membrane endothelial keratoplasty (DMEK) for Fuchs endothelial dystrophy: review of the first 50 consecutive cases. Eye. 2009;23:1990-8.





Two-day advanced keratoplasty wetlab instruction courses 2010

Deep anterior lamellar keratoplasty (DALK)

Descemet stripping endothelial keratoplasty (DSEK)

Descemet membrane endothelial keratoplasty (DMEK)

☞ DMEK: February 26/27 2010
(At Johns Hopkins, Baltimore, USA)

☞ DALK/DMEK: March 30/31, 2010

☞ DALK/DMEK: May 11/12, 2010

☞ DALK/DMEK: June 15/16, 2010


☞ DALK/DMEK: October 12/13, 2010

☞ DALK/DMEK: November 16/17, 2010

Each course is scheduled on a Tuesday/Wednesday. On Tuesday, the course participants join live surgery sessions; on Wednesday, various techniques are practised during educational wetlab sessions.

Level: Advanced - Corneal surgeons and senior eyebank technicians.

See www.nios.com for application form and update.



Course participants during the wetlab and at the Euromast in Rotterdam

First posterior lamellar keratoplasty (PLK) / deep lamellar endothelial keratoplasty (DLEK) series

Ten years after the first successful series of endothelial keratoplasty

From March 1998 to November 2001, the first successful series of posterior lamellar keratoplasty (PLK) or deep lamellar endothelial keratoplasty (DLEK) through a scleral incision was performed in The Netherlands (before switching to Descemet stripping endothelial keratoplasty (DSEK)). Ten years later, most patients in the PLK/DLEK series could be re-examined. In addition to documenting the condition of the transplanted cornea, we asked our pioneer-patients how they now felt about having the surgery performed, and how they had experienced the past ten years. Below the interview with Mrs Cornelissen-van Gils, whose story largely reflects those of the other patients.

☞ **How did you do before the surgery?**

“Well, what to say? I think I never did really see very well. When I was young, I used to work on the land. Harvesting vegetables. That was working out, and I also kept up with running my family. But I had to be more and more careful. People on the other side of the street, I could not really recognize anymore. If I was crossing the street with my children, I had to listen really well if there were no cars coming up. Just like a mother-duck, I never had an accident, but a lot of people in my village have often been using their brakes to the limit!”

☞ **How did you learn about the technique of Dr Melles?**

“My eye doctor referred me about twelve years ago. Dr Melles considered me a suitable patient for his technique. So I chose to do it. I thought, maybe he can learn a few things, so he can help other people.”

☞ **What do you remember about the surgery and thereafter?**

“Well, Dr Melles has indeed operated me then on my right eye. I even had to give my signature for him to do so. The operation and so on went very well - the result was really a revelation. I can't put it into words any better. I quickly noticed a lot of improvement. The smell of burning rubber disappeared from my life - this eye actually never gave any problem. Not so, my left eye...”

☞ **What about your left eye?**

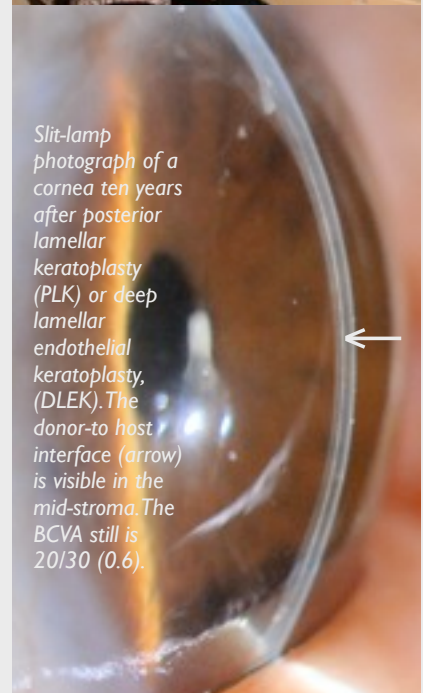
“Two years after the first operation, I needed a corneal transplant in the other eye. Back then, I could not choose for the same procedure, so they replaced my whole cornea with sutures. I always had bad luck with the left eye. I don't see much with it - about the same as before the operation. And it still feels always uncomfortable. I'd wish they'd given my Dr Melles' operation again!” [According to IRB protocol, DLEK was performed in only one eye at the time; red.]

☞ **How was your visit at the Cornea Clinic in Rotterdam?**

“I really enjoyed seeing Dr Melles again. Nothing has changed. And all people in the clinic were very supportive and friendly. And they measured my sight in both eyes, and they also found a difference, just as I said just now.”



Mrs Cornelissen - van Gils



Slit-lamp photograph of a cornea ten years after posterior lamellar keratoplasty (PLK) or deep lamellar endothelial keratoplasty, (DLEK). The donor-to host interface (arrow) is visible in the mid-stroma. The BCVA still is 20/30 (0.6).